

REVIEW

Open Access



# Relationship between resting-state functional connectivity and change in motor function after motor imagery intervention in patients with stroke: a scoping review

Kenya Tanamachi<sup>1,2</sup>, Wataru Kuwahara<sup>1,2</sup>, Megumi Okawada<sup>1,2</sup>, Shun Sasaki<sup>2</sup> and Fuminari Kaneko<sup>1,2\*</sup>

## Abstract

**Background** In clinical practice, motor imagery has been proposed as a treatment modality for stroke owing to its feasibility in patients with severe motor impairment. Motor imagery-based interventions can be categorized as open- or closed-loop. Closed-loop intervention is based on voluntary motor imagery and induced peripheral sensory afferent (e.g., Brain Computer Interface (BCI)-based interventions). Meanwhile, open-loop interventions include methods without voluntary motor imagery or sensory afferent. Resting-state functional connectivity (rs-FC) is defined as a significant temporal correlated signal among functionally related brain regions without any stimulus. rs-FC is a powerful tool for exploring the baseline characteristics of brain connectivity. Previous studies reported changes in rs-FC after motor imagery interventions. Systematic reviews also reported the effects of motor imagery-based interventions at the behavioral level. This study aimed to review and describe the relationship between the improvement in motor function and changes in rs-FC after motor imagery in patients with stroke.

**Review process** The literature review was based on Arksey and O'Malley's framework. PubMed, Ovid MEDLINE, Cochrane Central Register of Controlled Trials, and Web of Science were searched up to September 30, 2023. The included studies covered the following topics: illusion without voluntary action, motor imagery, action imitation, and BCI-based interventions. The correlation between rs-FC and motor function before and after the intervention was analyzed. After screening by two independent researchers, 13 studies on BCI-based intervention, motor imagery intervention, and kinesthetic illusion induced by visual stimulation therapy were included.

**Conclusion** All studies relating to motor imagery in this review reported improvement in motor function post-intervention. Furthermore, all those studies demonstrated a significant relationship between the change in motor function and rs-FC (e.g., sensorimotor network and parietal cortex).

**Keywords** Motor imagery, Brain-computer interface, Resting state functional connectivity, Stroke, Scoping review

\*Correspondence:

Fuminari Kaneko  
f-kaneko@tmu.ac.jp

<sup>1</sup> Department of Physical Therapy, Graduate School of Health Sciences, Tokyo Metropolitan University, 7-2-10 Higashi-Ogu, Arakawa-Ku, Tokyo, Japan

<sup>2</sup> Department of Rehabilitation Medicine, Keio University School of Medicine, 35 Shinanomachi, Shinjuku-ku, Tokyo, Japan

## Background

Stroke is one of the most prevalent neurological diseases worldwide. Importantly, it induces motor dysfunction and hinders the performance of activities of daily living. Up to 85% of survivors experience hemiparesis immediately after the stroke, resulting in impaired upper extremity function. In addition, 55 to 75% of survivors continue to experience limitations in upper extremity function,



© The Author(s) 2023. **Open Access** This article is licensed under a Creative Commons Attribution 4.0 International License, which permits use, sharing, adaptation, distribution and reproduction in any medium or format, as long as you give appropriate credit to the original author(s) and the source, provide a link to the Creative Commons licence, and indicate if changes were made. The images or other third party material in this article are included in the article's Creative Commons licence, unless indicated otherwise in a credit line to the material. If material is not included in the article's Creative Commons licence and your intended use is not permitted by statutory regulation or exceeds the permitted use, you will need to obtain permission directly from the copyright holder. To view a copy of this licence, visit <http://creativecommons.org/licenses/by/4.0/>. The Creative Commons Public Domain Dedication waiver (<http://creativecommons.org/publicdomain/zero/1.0/>) applies to the data made available in this article, unless otherwise stated in a credit line to the data.

even at 3–6 months after the event, further leading to a decline in health-related quality of life [1, 2].

Motor imagery involves as the mental presentation of an action without voluntary body movement [3]. The physiological effect was first represented as the regional cerebral blood flow during rest and planning of voluntary movement reported by Roland et al. [4] They reported that motor imagery activates central sites involved in normal voluntary movements. After more than 10 years, Yahagi and Kasai reported that the primary motor cortex excitability increased during motor imagery without gain modulation in the spinal reflex, using transcranial magnetic stimulation (TMS) [5, 6]. After their reports using TMS, a number of studies concerning the physiological effects of motor imagery have since reported [7–10]. In 2011, Aoyama demonstrated that the facilitatory effect depends on the voluntary effort level of the motor image in the soleus muscle without a change in H-reflex gain [11]. We previously demonstrated the negative effect of sustained rest during joint immobilization on facilitatory function of motor imagery [12]. In that research, we demonstrated that the facilitation effect in which the motor evoked potentials (MEP) during motor imagery was suppressed after immobilization along parallel with decreased muscular output. Furthermore, when the voluntary muscular activity level recovered to that of before the immobilization, MEP was restored to the normal level. These previous findings of the physiological effects indicate the potential use of motor imagery as a clinical treatment, including in stroke. Systematic reviews reported the effects of motor imagery for corticomotoneuronal excitability. In 2019, Dilena et al. [13] indicated that the excitability of the corticomotoneuronal system was enhanced by the kinesthetic illusion, which was induced through visual and tendon vibration.

An advantage of motor imagery intervention is that it may be feasible in patients with severely impaired motor function. Zimmermann-Schlatter et al. [14] conducted a systematic review in 2008 on the efficacy of motor imagery intervention in post-stroke rehabilitation. They found that an improvement in motor imagery, as evidenced by the Fugl-Meyer Assessment (FMA), can confer additional benefits to conventional therapy. Biosignal-based brain-computer interface (BCI) hold great potential for the motor rehabilitation of patients with stroke. Systematic reviews and meta-analyses reported the effects of BCI-based interventions. In 2017, Monge-Pereira et al. [15] indicated that BCI may be potentially beneficial in improving motor outcome measures, such as FMA, Action Research Arm Test (ARAT), and Wolf Motor Function Test (WMFT), in patients with stroke. Carvalho et al. [16] also reported in 2019 that BCI-based intervention, in conjunction with physical practice

(conventional or robot-assisted therapy), can enhance upper limb functional recovery. BCI-based intervention can categorize as a closed-loop intervention. In closed-loop intervention, voluntary motor imagery is examined through electroencephalography (EEG). The EEG-based BCI system uses this signal to drive exoskeletal robots and induces peripheral sensory afferent. Meanwhile, open-loop intervention involves methods without voluntary effort to reproduce motor imagery and/ or the absence of sensory afferent. Motor imagery interventions have been shown to be effective in improving motor function [17, 18].

Resting-state functional connectivity (rs-FC) is a powerful tool for exploring the baseline characteristics of brain connectivity. rs-FC is a significantly temporal correlated signal between functionally-related brain regions in the absence of any stimulus or task [19]. rs-FC measurable through functional magnetic resonance imaging (fMRI), EEG, and magnetoencephalography (MEG). According to previous studies, the intensity of rs-FC was related to behavioral measures, and repetition of a specific task modified the rs-FC between brain regions closely related to that task after stroke [20–23].

Previous studies investigating motor imagery intervention reported that the inter- and intra-hemispheric rs-FC differs in patients depending on stroke severity, becoming weak in patients with severe stroke [24]. Patients in the subacute-to-chronic phase after stroke exhibit diminished rs-FC between the primary motor cortex (PMC) of each hemisphere compared to the healthy controls [25]. The index of asymmetry was significantly correlated with motor function deficits, and the rs-FC between post-central gyrus (S1) and other regions indicated an asymmetrical difference [26], while rs-FC was increased in the ipsilesional (ipsi-) sensorimotor cortex during the neurofeedback intervention [27]. We investigated that relationship between rs-FC and motor function [28]. This study indicated indicate a linear relationship between rs-FC and improvement of motor function. Investigating the relationship between improvements in motor function and changes in rs-FC through motor imagery intervention can provide valuable insights into understanding this relationship. We hypothesized that resting-state brain function coupling underlies the improvement in motor function with motor imagery intervention. However, our hypothesis has not been reviewed. Therefore, the present review aimed to review and describe the status of these studies.

## Methods

### Search strategy

The literature review was based on the framework by Arksey and O'Malley [29]. The following describes the

phases of the framework adopted to conduct the scoping study: stage 1: identifying the research question; stage 2: identifying relevant studies; stage 3: study selection; stage 4: charting the data; and stage 5: collating, summarizing, and reporting the results.

The PubMed, Ovid MEDLINE, Cochrane Central Register of Controlled Trials, and Web of Science databases were accessed, and the search was completed on September 30, 2023.

The primary search was conducted using the following terms: (((illusion) OR ("motor image") OR ("motor imagery") OR ("motor images") OR ("mental practice") OR (Vibrator) OR (Vibration) OR (imitation) OR ("visual stimulation") OR (BCI) OR (BMI) OR ("brain computer interface") OR ("brain machine interface")) AND ((stroke) OR (CVA) OR ("cerebrovascular accident") OR ("cerebral infarct") OR ("cerebral hemorrhage") OR (hemiplegia) OR (hemiparesis) OR (ABI) OR ("acquired brain injury")))) AND ((fMRI) OR (MEG) OR (MRI) OR (TMS) OR ("Transcranial Magnetic Stimulation") OR (PET) OR (EEG) OR ("cortical network")) AND ("resting state").

Additionally, the following parameters were employed to identify the relevant studies: clinical trials/randomized controlled trials and other studies written in English language whose full texts were available. The publication date ranged from 2011 to 2023. Additional studies were identified via a manual search and duplicates were eliminated.

### Screening

The inclusion criteria were as follows:

- adult stroke patients (age > 18 years).
- treatment using the illusion without voluntary action, motor image, action imitation, and BCI-based interventions.
- the outcome measures included brain function tests, such as fMRI, MEG, transcranial magnetic stimulation, positron emission tomography, and EEG, and motor function tests, such as the FMA, modified Ashworth Scale (MAS), Box and Block Test, and ARAT.
- statistical analysis of the correlation between brain function and motor function before and after the intervention.
- studies published in English language.

The exclusion criteria were as follows:

- interventions such as mirror therapy and brain stimulation.
- non-peer-reviewed studies and papers that reported only the protocol.

Two reviewers screened potential studies to eliminate irrelevant studies based on the reference selection process and above-mentioned inclusion and exclusion criteria. If the relevance of a study was ambiguous from the abstract, it was ascertained from the full text.

### Data extraction and summarization

Data on the study design, participants, sample size, interventions used, intervention protocol, evaluation tools, and the outcome of the correlation between brain function and motor function were extracted (Fig. 1). The extracted data were summarized into a table by one independent author.

## Result

### Study selection

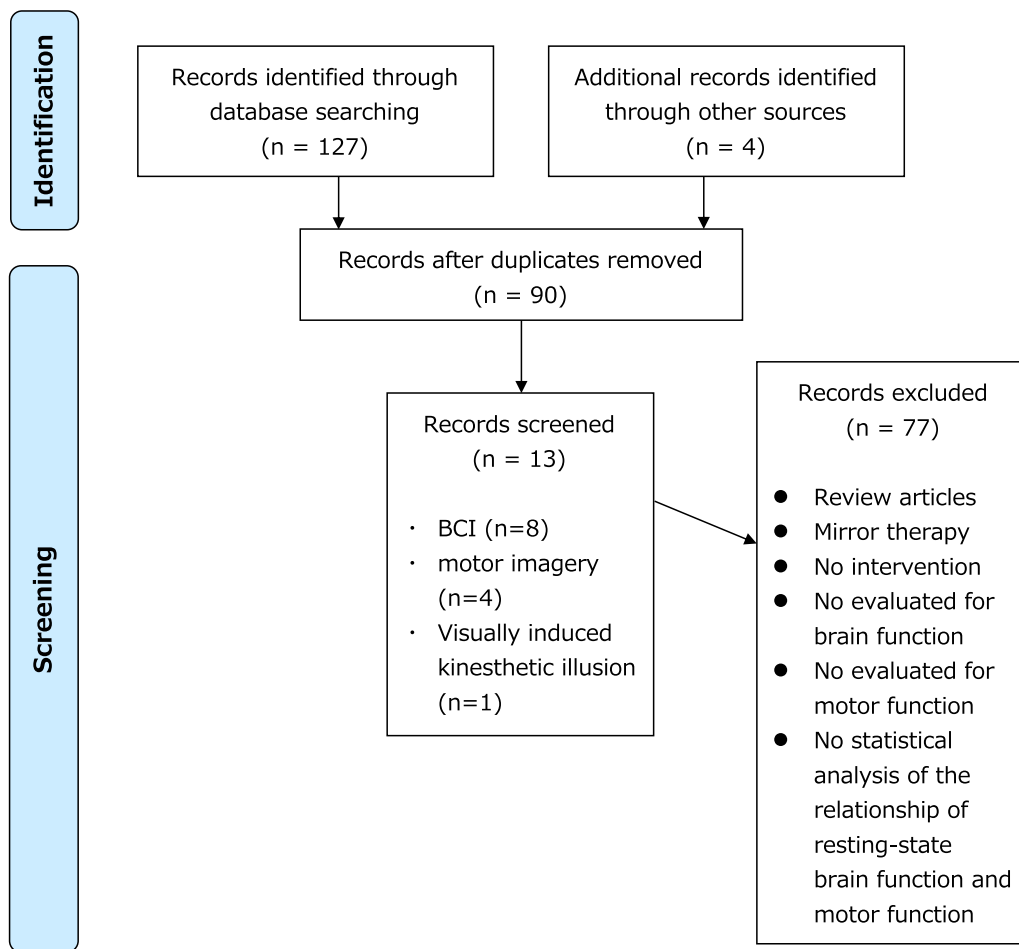
The characteristics of the included studies are listed in Tables 1 and 2. A total of 131 studies were identified through the database search, of which 41 were duplicates. Screening by two independent researchers yielded 13 studies on BCI-based interventions [30–37], motor imagery [38–41], and visually induced kinesthetic illusion (V-Kinesthetic illusion) [28] which were included.

### Participants

A total of 73 and 130 participants underwent open- and closed-loop interventions, respectively. The mean interval between the onset of stroke and open-loop intervention was 1.94 to 44.0 months and that for closed-loop intervention was 2.11 to 47.75 months. Three studies that used open-loop intervention evaluated patients in the acute stage (1.94–3.84 months) [38–40] and two studies evaluated patients in the chronic stage (10.15–44.0 months) [28, 41], while two studies that used closed-loop intervention evaluated patients in the acute stage (2.11–5.90 months) [31, 35], and six studies evaluated patients in the chronic stage (11.67–47.75 months). [30, 32–34, 36, 37].

### Training protocol

Open-loop intervention training sessions (e.g., motor imagery therapy) lasted 20–60 min, and the treatment course was 10–30 days. All participants received standard medical care and rehabilitation (conventional therapy). The protocol of the motor imagery task (without voluntary movement) was as follows: (1) opening and closing of the hand [38, 39], (2) arm elevation [38, 39], (3) flexion and extension of the elbow [38, 39], (4) grabbing [40], (5) pushing [40], (6) first clenching [40], (7) writing [40], (8) finger tapping [40], (9) brushing or combing hair [41], (10) picking up and bringing different types of fruit to the mouth [41], (11) extending the arm to pick up a cup from a cabinet, placing it on the counter and gently



**Fig. 1** A flow diagram of the selection process

releasing it [41], (12) cleaning the kitchen counter using a cloth [41], and (13) observing a video of opening and closure of a hand [28].

Closed-loop intervention training was conducted over 10–60 sessions, and the duration of each session was different. Three studies used conventional therapy. The protocol of the motor imagery task was as follows: (1) opening and closing the affected hand [30, 32], (2) the state of the muscles as the hand stretches or contracts [31], (3) grasping or releasing a cup according to the instruction [33–36], and (2) reaching in eight directions [37]. The closed-loop intervention was assisted by a robotic equipment as follows; hand grasp and open [30–36] and the MANUS robot in moving the stroke-affected limb toward the goal displayed on the screen [37].

#### Outcome measures

Nine studies used resting-state brain function as evaluated with fMRI as the outcome measure [28, 31, 33–35, 37–41] (one study additionally used EEG [33]), EEG used

in two studies, [30, 32] and MEG was used in one study [36].

Motor function outcome measures were used to assess the functional aspects or activities of daily living. Twelve studies used the FMA [28, 30–35, 37–41], five studies used the ARAT [28, 30, 32, 35, 36], three studies used the grip strength [30, 32, 36], two studies used the modified Ashworth Scale (MAS) and Morticity Index [30, 32], and one study used the WMFT [35] to measure upper limb motor function. One study used the modified Barthel index [38] and one study used motor activity log [28] as measures of activities of daily living.

#### Relationship between brain function and motor function

Open-loop intervention studies used seed-based FC analysis, graph theory, and spectral Granger causality (GC) measures for MRI analysis. Seed-based FC analysis was used to identify temporally correlated brain regions using blood-oxygen-level-dependent (BOLD) signal fluctuations in the regions of interest. Three studies used

**Table 1** Literature summary of the open-loop intervention

Author (year)	After onset	Sample size	Type of intervention	Task	Number of sessions	CRT	Outcome measure of brain function	Outcome of motor function	Relationship between rs-FC and motor function
Wang X et al. (2020) [38]	121.19±37.33 days	16	Motor imagery training	Imagine basic movements, such as opening and closing of the hand, arm elevation, flexion and extension of the elbow	<ul style="list-style-type: none"> <li>All patients received 3 h of CRT per day, 5 days per week for 4 weeks</li> <li>After each day's CRT, patients received Motor imagery training (30 min)</li> </ul>	○	fMRI	FMA, MBI	<ul style="list-style-type: none"> <li>Fractional amplitude of low-frequency fluctuations in the slow-5 band in the ipsi-IPL was positively correlated with the FMA score</li> <li>The ipsi-IPL with the bilateral PHG was increased after motor imagery intervention correlated with the improvement of FMA score</li> <li>The ipsi-IPL with the bilateral MCG, the contr-MeFG was decreased after motor imagery intervention correlated with the improvement of FMA score</li> </ul>
Wang H et al. (2019) [39]	121.19±37.33 days	16	Motor imagery training	Imagine basic movements, such as opening and closing of the hand, arm elevation, flexion and extension of the elbow	<ul style="list-style-type: none"> <li>All patients received 3 h of CRT per day, 5 days per week for 4 weeks</li> <li>After each day's CRT, patients received Motor imagery training (30 min)</li> </ul>	○	fMRI	FMA	<ul style="list-style-type: none"> <li>The increment of clustering coefficient was significantly positively correlated with improvement of upper limb FMA score</li> </ul>
Zhang Y et al. (2016) [40]	59.19±15.52 days	17	Motor imagery training	Imagine the actual motions such as grabbing, pushing, fist clenching, writing and finger tapping	<ul style="list-style-type: none"> <li>30 min, 30 days + CRT</li> </ul>	○	fMRI	FMA	<ul style="list-style-type: none"> <li>Positive correlation between bilateral PMC and the FMA score</li> </ul>

**Table 1** (continued)

Author (year)	After onset	Sample size	Type of intervention	Task	Number of sessions	CRT	Outcome measure of brain function	Outcome of motor function	Relationship between rs-FC and motor function
Bajaj S et al. (2015) [41]	10.15 ± 13.40 months	13	Motor imagery training	Imagine the actual motions such as 1) brushing or combing hair, 2) picking up and bringing different types of fruit to their mouth, 3) extending their arm to pick up a cup from a cabinet and place it on the counter and gently release it, and 4) cleaning the kitchen counter using a cloth	• 4 h per day (8-30 min session)	○	fMRI (Spectral Granger causality measures)	FMA	• Positive correlation between Granger causality differences (from SMA to lateral PMC) and FMA score in the motor imagery intervention group
Kaneko et al. (2019) [28]	44 ± 29.01 months	11	V-Kinesthetic illusion	Video observation of hand opening and closing	• 20 min V-Kinesthetic illusion + 60 min CRT, 10 days	○	fMRI	FMA, MAS, ARAT, MAL	• Changes in the relationship (negative to positive) between motor function and the inter-hemispheric rs-FC of the bilateral IPS, and disappearance of the significant negative correlation between the motor functions and the inter-hemispheric rs-FC of the IPL in the unaffected side and PMC occurred in parallel with the behavioral changes

ANG angular gyrus, ARAT Action Reach Arm Test, CRT conventional rehabilitation, FMA Fugle-Meyer Assessment, fMRI functional magnetic resonance imaging, IFG inferior frontal gyrus, INS insula, IPL inferior parietal lobule, IPS intraparietal sulcus, IOG inferior occipital gyrus, MAL Motor activity Log, MAS modified Ashworth Scale, MBI modified Barthel index, MCG middle cingulate gyrus, MEG magnetoencephalography, MeFG medial frontal gyrus, MIFG middle frontal gyrus, PHG parahippocampal gyrus, PMC premotor cortex, rs-FC resting state functional connectivity, SFG superior frontal gyrus, SMA supplementary motor area, STG superior temporal gyrus, ipsi- ipsilesional, cont- contralesional

**Table 2** Literature summary of the closed-loop intervention

Author (year)	After onset	Sample size	Type of intervention	Task	Number of sessions	CRT	Outcome measure of brain function	Outcome of motor function	Relationship between rs-FC and motor function
Rustamov N et al. (2023) [30]	68.2 ± 78.2 months	30	EEG-based BCI	Imagine opening and closing their affected hand	60 sessions (5sessions/week) 60 min	×	EEG	FMA, ARAT, Motricity Index, Gross Grasp, MAS	<ul style="list-style-type: none"> <li>FMA, ARAT and Motricity Index significant correlated with an increased coupling of theta and gamma frequencies in the motor regions</li> </ul>
Ma ZZ et al. (2023) [31]	5.90 ± 2.99 months	20	EEG-based BCI	Imagine the state of the muscles as the right or left-hand stretches or contracts	10 sessions (5sessions/week) 40 min	×	EEG, fMRI	FMA	<ul style="list-style-type: none"> <li>The assortativity of the dorsal attention network was positively correlated with the gain of the FMA-UE after treatment</li> </ul>
Rustamov N et al. (2022) [32]	65.7 ± 15.5 months	17	EEG-based BCI	Imagine opening and closing their affected hand	60 sessions (5sessions/week) 60 min	○	EEG	FMA, AMAT, Motricity Index, MAS	<ul style="list-style-type: none"> <li>Theta-gamma coupling in bi-PMC was enhanced and was significantly correlated across BCI intervention sessions</li> </ul>
Yuan K et al. (2021) [33]	3.98 ± 3.05 years	14	EEG-based BCI	Imagine either grasping or releasing a cup following the instruction displayed on the monitor	20 sessions (3–5sessions/week) 30 min	×	EEG + fMRI	FMA	<ul style="list-style-type: none"> <li>Information flow change from cont-BAG to ipsi-PMC and SMA to ipsi-PMC significantly correlated with the FMA score change</li> <li>rs-FC change between ipsi-PMC and cont-BAG was positively correlated with the FMA</li> </ul>



**Table 2** (continued)

Author (year)	After onset	Sample size	Type of intervention	Task	Number of sessions	CRT	Outcome measure of brain function	Outcome of motor function	Relationship between rs-FC and motor function
Yuan K et al. (2020) [34]	3.98 ± 3.05 years	14	EEG-based BCI	Imagine either grasping or releasing a cup following the instruction displayed on the monitor	20 sessions (3–5 sessions/week) 30 min	×	fMRI	FMA	<ul style="list-style-type: none"> <li>Correlation analysis also showed that interhemispheric rs-FC change between Pre and Post sessions was significantly correlated with FMA score change</li> <li>FMA score change was significantly correlated with rs-FC change between ipsi-PMC seed and the significant cluster in the contralateral premotor area</li> <li>FMA score change was significantly correlated with rs-FC change between ipsi-SMA seed and the significant cluster in bilateral SPL</li> </ul>
Wu Q et al. (2019) [35]	2.11 ± 0.3 months	25	EEG-based BCI	Imagine grasping or releasing a cup with the affected hand, after an image-inverted video taken prior of the unaffected hand	20 sessions (5 sessions/week) 60 min	○	fMRI	FMA, ARAT, WMFT	<ul style="list-style-type: none"> <li>After comprehensive rehabilitation, including BCI training, increases in rs-FC between the left BA5 and right BA48 were positively correlated with clinical scores</li> <li>post training: upper limb FMA post score, ARAT post score, and WMFT post score</li> </ul>



**Table 2** (continued)

Author (year)	After onset	Sample size	Type of intervention	Task	Number of sessions	CRT	Outcome measure of brain function	Outcome of motor function	Relationship between rs-FC and motor function
Rathée D et al. (2019) [36]	21.8 ± 1.1 months	4	EEG-based BCI	Presentation of a cue to perform either a left or right-hand grasp attempt	12 sessions 30 min	×	MEG	ARAT, grip- strength	<ul style="list-style-type: none"> <li>The motor network involving the precentral gyrus (i.e., PMC), postcentral gyrus (i.e., S1), and SMA brain regions became stronger with upper limb functional recovery</li> </ul>
Várkuti B et al. (2013) [37]	11.67 ± 13.51 months	6	EEG-based BCI	8-Direction reaching with MANUS robot	12 rehabilitation sessions in approximately 1 month	×	fMRI	FMA	<ul style="list-style-type: none"> <li>Increases in rs-FC of the SMA, bi-PMC, and parts of the visual system with mostly association cortex regions and the cerebellum correlated with upper limb functional improvement</li> </ul>

*AMAT* Arm Motor Ability Test, *ARAT* Action Reach Arm Test, *BA* Brodmann area, *BCI* brain-computer interface, *CRT* conventional rehabilitation, *EEG* electroencephalography, *FMA* Fugle-Meyer Assessment, *fMRI* functional magnetic resonance imaging, *IPL* inferior parietal lobule, *IPS* intraparietal sulcus, *MAS* modified Ashworth Scale, *MCI* modified Barthel index, *MCG* magnetoencephalography, *MEG* magnetoencephalography, *PHG* parahippocampal gyrus, *PMC* premotor cortex, *rs-FC* resting state functional connectivity, *SMA* supplementary motor area, *SPL* Superior parietal lobule, *WMFT* Wolf Motor Function Test, *ipsr*- ipsilesional, *contr*-contralateral, *bi*- bilateral

seed-based FC analysis, which indicated the following: (1) fractional amplitude of low-frequency fluctuations in the slow-5 band in the ipsi-inferior parietal gyrus (IPL) was positively correlated with the FMA [38]; (2) The ipsi-IPL with the bilateral (bi-) parahippocampal gyrus (PHG) was increased after motor imagery intervention correlated with the improvement of FMA score [38]; (3) The ipsi-IPL with the bi-middle cingulate gyrus (MCG), the contralesional (cont-) medial frontal gyrus (MeFG) was decreased after motor imagery intervention correlated with the improvement of FMA score. [38]; (4) the rs-FC between the bi-PMC was positively correlated with the FMA [40]; and (5) the relationship (negative to positive) between the interhemispheric rs-FC of the bi-IPS and FMA changes and the significant negative correlation between the FMA and interhemispheric rs-FC of the IPL disappeared on the unaffected side and premotor cortex after the intervention [28]. One study, which used graph theory, indicated that the clustering coefficient was significantly positively correlation with the FMA [26]. The study that used spectral GC measures indicated a positive correlation between GC differences (from the supplementary motor area (SMA) to the lateral premotor cortex) and FMA [41].

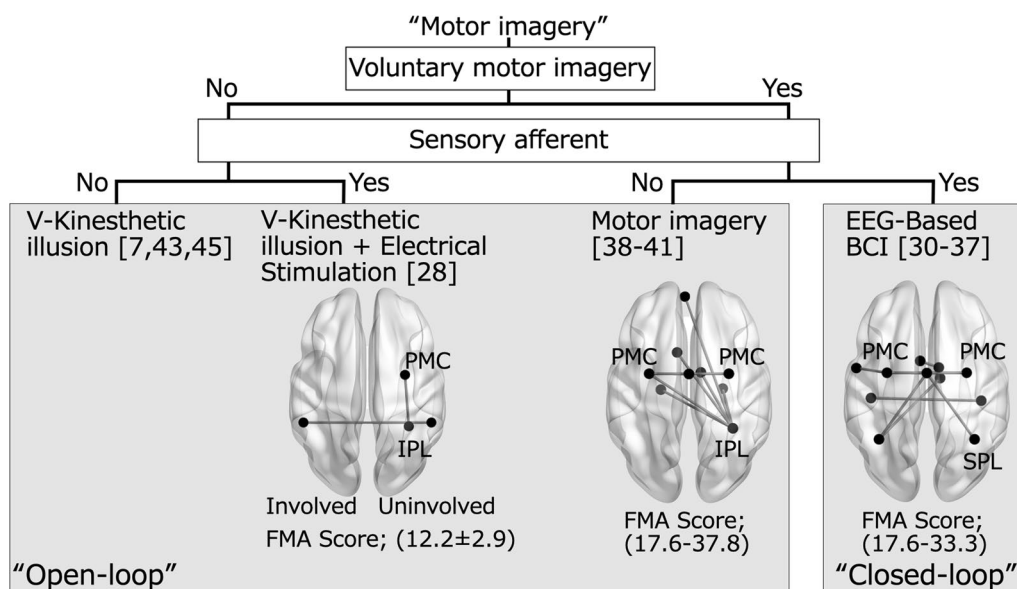
Closed-loop intervention studies used seed-based FC analysis and EEG and MEG parameters. Five studies used seed-based FC analysis and reported the following: (1) the rs-FC change between the ipsi-PMC and cont-Brodmann area (BA)6 was positively correlated with FMA [33]; (2) the FMA score altered with changes in the

interhemispheric rs-FC [34]; (3) the rs-FC between the ipsi-PMC with the cont-premotor area and ipsi-SMA of the bi-superior parietal lobule (SPL) was positively correlated with FMA [34]; (4) the changes in interhemispheric rs-FC and FMA score were positive correlated [34]; (5) the left BA5 and right BA48 were positively correlated with the FMA, ARAT, and WMFT [35]; (6) the rs-FC of the SMA, cont- and ipsi-PMC, visuospatial system and cerebellum correlated with FMA [35]. Three study used EEG parameter analysis and reported the following: (1) FMA, ARAT and Motricity Index significant correlated with increased coupling of theta and gamma frequencies in the motor regions [30], (2) Theta-gamma coupling was enhanced bi-PMC and showed significant correlations across BCI intervention sessions [32], and (3) the information flow change from the cont-PMA to the ipsi-PMC and SMA to the ipsi-PMC were significantly correlated with the FMA score [33]. One study, which used MEG parameters, reported that the motor network involving the PMC, S1, and SMA brain regions became stronger with upper-limb functional recovery [36].

**Discussion**

**Summary of evidence**

The categories of motor imagery interventions extracted in this review and the brain networks that were associated with changes in motor function are summarized in Fig. 2. In closed-loop intervention, voluntary motor imagery is examined through electroencephalography (EEG). The EEG-based BCI system uses this signal to



**Fig. 2** Categories of motor imagery intervention and brain regions associated with improved motor function and changes in rs-FC. The unified right hemisphere as an uninvolved hemisphere. FMA Score indicate range of mean score in before intervention (The article using V-Kinesthetic illusion + Electrical stimulation was indicated as mean ± SD)

drive exoskeletal robots and induces peripheral sensory afferent. Then, in BCI-based intervention voluntary motor imagery can be modulated based on sensory afferent, we categorized this intervention as a closed-loop. Meanwhile, open-loop intervention involves methods without voluntary effort to reproduce motor imagery and/ or the absence of sensory afferent. All 13 studies were included in this review disturbed motor function after stroke improved following intervention in all studies. Furthermore, the relationship between the change in motor function and rs-FC, including the sensorimotor network and parietal cortex. Previous studies suggested the effectiveness of open- and closed-loop interventions in improving motor function [14–16]. Exploring the correlation between the improvement in motor function and changes in rs-FC following motor imagery intervention can help elucidates the underlying causality behind this relationship.

#### **Phases of stroke during the intervention**

Functional recovery after stroke is known to reach a plateau within 3–6 months, and 85% of stroke survivors experience paralysis and 55–75% have upper limb dysfunction, which are associated with a diminished health-related quality of life [1]. All studies selected for this review included patients in the subacute to chronic phase and exhibited recovery of motor function following open- or closed-loop intervention. Both types of intervention have the potential to improve motor function in the chronic phase after stroke.

#### **Differences between open-loop and closed-loop intervention protocols**

The most salient difference between the open-loop and closed-loop intervention protocols was the inclusion of combined conventional therapy in the former. Open-loop intervention was combined with conventional therapy in all studies. Open-loop interventions included motor imagery and V-Kinesthetic illusion. Open-loop intervention entails repetitive cognitive recall of body movements without voluntary body movements as sensory afferent of the motor imagery. V-Kinesthetic illusion is defined as the psychological phenomenon in which a person who is resting feels as if a part of their own body is moving or feels the desire to move a body part while watching film footage of a moving body part [7]. Kaneko et al. refer to this therapy as 'KINVIS therapy' because abbreviated from kinesthetic illusion induced by visual stimulation, and the effect of KINVIS therapy was explored in the clinical trials [10, 28, 42–44]. In several studies, V-Kinesthetic illusion while neuromuscular electrical stimulation was applied to the agonist muscle to the one causing the movement in the film. In V-Kinesthetic illusion, motor

imagery was not a picture but kinesthetic perception. In addition to this step, motor imagery is passively induced, and brain activity similar to that during exercise is obtained [45]. Such as V-Kinesthetic illusion, passively induced motor imagery following the cognitive replacement was categorized as open-loop intervention in this review.

Unintentionally generated motor imagery (e.g., observation of movement) is called implicit motor imagery [46]. According to Hanakawa et al. [47, 48], there is additional evidence suggesting that the participants' neural activity during motor imagery resembled that observed just prior to actual finger movements. V-Kinesthetic illusion is without intentionally movement and passively induced motor imagery during observation movements. V-Kinesthetic illusion can be represented as virtual kinesthetic perception, and it can have markedly vivid kinesthetic perception than simple observation of movement [7]. Therefore, we interpret it as implicit motor imagery.

Closed-loop intervention, which uses BCI as feedback for motor imagery, can activate the neural pathway of motor control via motor intention and the actual movement [49]. BCI-based interventions can ensure better active engagement and motivation of patients compared to conventional therapy [50]. Closed-loop intervention does not necessarily require conventional therapy; EEG-based BCI occur with joint movements associated with motor imagery, which may be equivalent to active movement. [51] In this case, conventional therapy may not be required for impairment of motor function.

#### **Relationship between brain and motor function after motor imagery intervention**

Previous studies used fMRI to show that the motor imagery and perception of a kinesthetic illusion were associated with activation of the primary motor cortex, premotor cortex, SPL, primary somato-sensory cortex, SMA, IPL, cingulate motor area, and cerebellum [52–58]. BCI-based intervention was associated with rs-FC networks related to the motor attempt [59–61].

In 2019, Kaneko et al. [28]. reported that the relationship between the pre-test rs-FC and the improvement in motor function after V-kinesthetic illusion therapy showed a significant negative correlation with affected IPS-unaffected IPS to the ARAT and a positive correlation from affected SMG-Vermis to the ARAT. Miyawaki et al. [62] explored the effect of V-kinesthetic illusion therapy with therapeutic exercise (TheEx) on motor functions through spasticity. They used a mediation model in which the indirect effect was evaluated with path analyses in structural equation modeling. V-Kinesthetic illusion therapy combined with TheEx leads to a reduction in the MAS score, resulting in improvements

in FMA and ARAT scores. Notably, the mediation model revealed that there was no significant direct impact of V-Kinesthetic illusion therapy on FMA and ARAT scores. These findings imply that the influence of V-Kinesthetic illusion therapy with TheEx on upper limb motor function is indirectly mediated through its effect on spasticity. Moreover, rs-FC between affected IPS-unaffected IPS was associated with the motor function of hands and fingers, unaffected IPL-unaffected PMd was associated with the motor function of shoulders and elbows and affected IPS-unaffected IPS or affected SMG-Vermis reflect the change in motor function. Thus, investigating the relationship between rs-FC and improvement in motor function with therapy may reveal a causal relationship between the improvement in motor function and therapy.

All studies in this review performed open-loop intervention without voluntary movement and the absence of sensory afferent or closed-loop intervention with sensory afferent of motor imagery using BCI. In both types of interventions, improvements in motor function were related to the change of rs-FC, including the sensorimotor network and parietal cortex. In the closed-loop intervention, proprioceptive and visual inputs were associated with movement. This may induce a sense of body ownership and kinesthetic perception and increase the rs-FC of the motor-related function and parietal cortex.

Previous studies have not sufficiently focus on established treatments to improve severe impairment of upper limb motor function. In our previous clinical trial with V-Kinesthetic illusion [28], the baseline FMA of stroke patients included lower than that of other motor imagery interventions. The V-Kinesthetic illusion is not limited by motor impairment and may be better suited for patients with severe motor paralysis.

Closed-loop interventions (EEG-based BCI) have recently been proposed as a stroke neurorehabilitation strategy to improve symptoms, including paralysis, cognitive disorders, and aphasia [35]. Despite the substantial heterogeneity in the available literature, there is a consensus that closed-loop intervention can help improve upper limb motor function in patients with stroke [16, 63]. Furthermore, the result of this review indicated that closed-loop intervention, as with open-loop, improves motor function and induces the changes in the rs-FC.

Several studies already showed that motor imagery increases corticospinal excitability [5–13]. The changes in rs-FC following the motor imagery intervention in the present study may represent a brain network enhanced by use-dependent plasticity due to repetition of motor imagery [64, 65].

Future studies should examine not only the assessment of motor function but also brain function because the

latter may help clarify the mechanism of motor function improvement.

### Limitations

The quality of evidence was not assessed in this review. The type and severity of the participants' disability, as well as the intervention methodologies and protocols, were not considered. A high-quality systematic review with a larger scope and with control for factors affecting the effectiveness of rehabilitation (e.g., type of lesion, the phase of recovery, dosage, and intensity of training) is necessary to address these limitations in the future.

### Conclusion

This review shows that rs-FC is related with change in motor function after motor imagery intervention. There are many similarities between the open-loop and closed-loop interventions with respect to the brain regions, such as the sensorimotor network and the parietal cortex, which are correlated with the change in motor function. These findings may provide a neurological basis for a clinician considering a motor imagery intervention. It should be noted, however, that the validation of the effectiveness of motor imagery interventions still involves heterogeneity to date. Further studies are required to strengthen the evidence on intervention protocols and provide detailed information regarding the application of different interventions to optimize practice benefit and outcomes.

### Abbreviations

AG	Angular gyrus
ARAT	Action Reach Arm Test
BA	Brodmann area
BBS	Berg Balance Scale
BOLD	Blood-oxygen-level-dependent
BCI	Brain-computer interface
EEG	Electroencephalography
EMG	Electromyography
FMA	Fugle-Meyer Assessment
fMRI	Functional magnetic resonance imaging
IFG	Inferior frontal gyrus
INS	Insula
IOG	Inferior occipital gyrus
IPL	Inferior parietal lobule
IPS	Intraparietal sulcus
MAS	Modified Ashworth Scale
MCG	Middle cingulate gyrus
MeFG	Medial frontal gyrus
MEG	Magnetoencephalography
MEP	Motor evoked potential
MiFG	Middle frontal gyrus
MTG	Middle temporal gyrus
PHG	Parahippocampal gyrus
PMC	Primary motor cortex
rs-FC	Resting-state functional connectivity
SFG	Superior frontal gyrus
SMA	Supplementary motor area
SMG	Supramarginal gyrus
SPL	Superior parietal lobule

STG Superior temporal gyrus  
WMFT Wolf Motor Function Test

### Acknowledgements

We would like to thank Editage ([www.editage.com](http://www.editage.com)) for English language editing.

### Author contributions

KT developed the framework, performed the search and study selection, evaluated the candidate studies, and drafted the manuscript. SS evaluated the candidate studies during the study selection process and revised the manuscript. FK supervised the process of this review, participated in the selection process, and revised the manuscript. WK and MO revised the manuscript. All authors read and approved the final manuscript.

### Funding

This study was supported by JSPS KAKENHI (Grant Numbers 23H00458).

### Availability of data and materials

Not applicable.

### Declarations

#### Ethics approval and consent to participate

Not applicable.

#### Consent for publication

Not applicable.

#### Competing interests

The authors declare that they have no competing interests.

Received: 19 June 2023 Accepted: 12 November 2023

Published online: 18 November 2023

### References

- Levin MF, Kleim JA, Wolf SL. What do motor "recovery" and "compensation" mean in patients following stroke? *Neurorehabil Neural Repair*. 2009;23(4):313–9.
- Hendricks HT, van Limbeek J, Geurts AC, Zwartz MJ. Motor recovery after stroke: a systematic review of the literature. *Arch Phys Med Rehabil*. 2002;83(11):1629–37.
- Guillot A, Collet C, Nguyen VA, Malouin F, Richards C, Doyon J. Brain activity during visual versus kinesthetic imagery: an fMRI study. *Hum Brain Mapp*. 2009;30(7):2157–72.
- Roland PE, Larsen B, Lassen NA, Skinhøj E. Supplementary motor area and other cortical areas in organization of voluntary movements in man. *J Neurophysiol*. 1980;43(1):118–36.
- Yahagi S, Shimura K, Kasai T. An increase in cortical excitability with no change in spinal excitability during motor imagery. *Percept Mot Skills*. 1996;83(1):288–90.
- Kasai T, Kawai S, Kawanishi M, Yahagi S. Evidence for facilitation of motor evoked potentials (MEPs) induced by motor imagery. *Brain Res*. 1997;744(1):147–50.
- Kaneko F, Yasojima T, Kizuka T. Kinesthetic illusory feeling induced by a finger movement movie effects on corticomotor excitability. *Neuroscience*. 2007;149(4):976–84.
- Aoyama T, Kaneko F, Hayami T, Shibata E. The effects of kinesthetic illusory sensation induced by a visual stimulus on the corticomotor excitability of the leg muscles. *Neurosci Lett*. 2012;514(1):106–9.
- Kaneko F, Shibata E, Hayami T, Nagahata K, Aoyama T. The association of motor imagery and kinesthetic illusion prolongs the effect of transcranial direct current stimulation on corticospinal tract excitability. *J Neuroeng Rehabil*. 2016;13:36.
- Kaneko F, Inada T. Acute effect of visually induced kinesthetic illusion in patients with stroke: a preliminary report. *Int J Neurorehabil*. 2016;3:212.
- Aoyama T, Kaneko F. The effect of motor imagery on gain modulation of the spinal reflex. *Brain Res*. 2011;1372:41–8.
- Kaneko F, Murakami T, Onari K, Kurumadani H, Kawaguchi K. Decreased cortical excitability during motor imagery after disuse of an upper limb in humans. *Clin Neurophysiol*. 2003;114(12):2397–403.
- Dilena A, Todd G, Berryman C, Rio E, Stanton TR. What is the effect of bodily illusions on corticomotor excitability? A systematic review. *PLoS ONE*. 2019;14(8): e0219754.
- Zimmermann-Schlatter A, Schuster C, Puhan MA, Siekierka E, Steurer J. Efficacy of motor imagery in post-stroke rehabilitation: a systematic review. *J Neuroeng Rehabil*. 2008;5:8.
- Monge-Pereira E, Casatorres Perez-Higueras I, Fernandez-Gonzalez P, Ibanez-Pereda J, Serrano JI, Molina-Rueda F. Training cortical signals by means of a BMI-EEG system, its evolution and intervention. A case report. *Rev Neurol*. 2017;64(8):362–6.
- Carvalho R, Dias N, Cerqueira JJ. Brain-machine interface of upper limb recovery in stroke patients rehabilitation: a systematic review. *Physiother Res Int*. 2019;24(2): e1764.
- Guerra ZF, Lucchetti ALG, Lucchetti G. Motor imagery training after stroke: a systematic review and meta-analysis of randomized controlled trials. *J Neurol Phys Ther*. 2017;41(4):205–14.
- Langhorne P, Coupar F, Pollock A. Motor recovery after stroke: a systematic review. *Lancet Neurol*. 2009;8(8):741–54.
- Biswal B. Resting-state functional connectivity. In: Toga AW, editor. *Brain mapping*. Waltham: Academic Press; 2015. p. 581–5.
- Baldassarre A, Lewis CM, Committeri G, Snyder AZ, Romani GL, Corbetta M. Individual variability in functional connectivity predicts performance of a perceptual task. *Proc Natl Acad Sci U S A*. 2012;109(9):3516–21.
- Cole MW, Yarkoni T, Repovs G, Anticevic A, Braver TS. Global connectivity of prefrontal cortex predicts cognitive control and intelligence. *J Neurosci*. 2012;32(26):8988–99.
- Powers AR 3rd, Hevey MA, Wallace MT. Neural correlates of multisensory perceptual learning. *J Neurosci*. 2012;32(18):6263–74.
- Vahdat S, Darainy M, Milner TE, Ostry DJ. Functionally specific changes in resting-state sensorimotor networks after motor learning. *J Neurosci*. 2011;31(47):16907–15.
- De Bruyn N, Meyer S, Kessner SS, Essers B, Cheng B, Thomalla G, et al. Functional network connectivity is altered in patients with upper limb somatosensory impairments in the acute phase post stroke: a cross-sectional study. *PLoS ONE*. 2018;13(10): e0205693.
- Zhang Y, Li K-S, Ning Y-Z, Fu C-H, Liu H-W, Han X, et al. Altered structural and functional connectivity between the bilateral primary motor cortex in unilateral subcortical stroke: a multimodal magnetic resonance imaging study. *Medicine*. 2016;95(31): e4534.
- Frias I, Starrs F, Gisiger T, Minuk J, Thiel A, Paquette C. Interhemispheric connectivity of primary sensory cortex is associated with motor impairment after stroke. *Sci Rep*. 2018;8(1):12601.
- Tsuchimoto S, Shindo K, Hotta F, Hanakawa T, Liu M, Ushiba J. Sensorimotor connectivity after motor exercise with neurofeedback in post-stroke patients with hemiplegia. *Neuroscience*. 2019;416:109–25.
- Kaneko F, Shindo K, Yoneta M, Okawada M, Akaboshi K, Liu M. A case series clinical trial of a novel approach using augmented reality that inspires self-body cognition in patients with stroke: effects on motor function and resting-state brain functional connectivity. *Front Syst Neurosci*. 2019;13:76.
- Arksey H, O'Malley L. Scoping studies: towards a methodological framework. *Int J Soc Res Methodol*. 2005;8(1):19–32.
- Rustamov N, Souders L, Sheehan L, Carter A, Leuthardt EC. IpsiHand brain-computer interface therapy induces broad upper extremity motor recovery in chronic stroke. *medRxiv* 2023.
- Ma ZZ, Wu JJ, Hua XY, Zheng MX, Xing XX, Ma J, et al. Evidence of neuroplasticity with brain-computer interface in a randomized trial for post-stroke rehabilitation: a graph-theoretic study of subnetwork analysis. *Front Neurol*. 2023;14:1135466.
- Rustamov N, Humphries J, Carter A, Leuthardt EC. Theta-gamma coupling as a cortical biomarker of brain-computer interface-mediated motor recovery in chronic stroke. *Brain Commun*. 2022;4(3): fca136.
- Yuan K, Chen C, Wang X, Chu WCW, Tong RKY. BCI training effects on chronic stroke correlate with functional reorganization in motor-related regions: a concurrent EEG and fMRI study. *Brain Sci*. 2021;11(1):56.



34. Yuan K, Wang X, Chen C, Lau CC, Chu WC, Tong RK. Interhemispheric functional reorganization and its structural base after BCI-guided upper-limb training in chronic stroke. *IEEE Trans Neural Syst Rehabil Eng*. 2020;28(11):2525–36.
35. Wu Q, Yue Z, Ge Y, Ma D, Yin H, Zhao H, et al. Brain functional networks study of subacute stroke patients with upper limb dysfunction after comprehensive rehabilitation including BCI training. *Front Neurol*. 2019;10:1419.
36. Rathee D, Chowdhury A, Meena YK, Dutta A, McDonough S, Prasad G. Brain-machine interface-driven post-stroke upper-limb functional recovery correlates with beta-band mediated cortical networks. *IEEE Trans Neural Syst Rehabil Eng*. 2019;27(5):1020–31.
37. Várkuti B, Guan C, Pan Y, Phua KS, Ang KK, Kuah CW, et al. Resting state changes in functional connectivity correlate with movement recovery for BCI and robot-assisted upper-extremity training after stroke. *Neurorehabil Neural Repair*. 2013;27(1):53–62.
38. Wang X, Wang HW, Xiong X, Sun CH, Zhu B, Xu YM, et al. Motor imagery training after stroke increases slow-5 oscillations and functional connectivity in the ipsilesional inferior parietal lobule. *Neurorehabil Neural Repair*. 2020;34(4):321–32.
39. Wang H, Xu G, Wang X, Sun C, Zhu B, Fan M, et al. The reorganization of resting-state brain networks associated with motor imagery training in chronic stroke patients. *IEEE Trans Neural Syst Rehabil Eng*. 2019;27(10):2237–45.
40. Zhang Y, Liu H, Wang L, Yang J, Yan R, Zhang J, et al. Relationship between functional connectivity and motor function assessment in stroke patients with hemiplegia: a resting-state functional MRI study. *Neuroradiology*. 2016;58(5):503–11.
41. Bajaj S, Butler AJ, Drake D, Dhamala M. Functional organization and restoration of the brain motor-execution network after stroke and rehabilitation. *Front Hum Neurosci* 2015;9:173.
42. Okawada M, Inada T, Matsuda N, Motozawa S, Yoneta M, Sasaki S, et al. Effects of kinesthetic illusion induced by visual stimulation (KINVIS) therapy on patients with stroke in the subacute phase: a visual analysis based on paralysis severity. *Neurocase*. 2022;28(2):199–205.
43. Takahashi R, Koiwa M, Ide W, Okawada M, Akaboshi K, Kaneko F. Visually induced kinaesthetic illusion combined with therapeutic exercise for patients with chronic stroke: a pilot study. *J Rehabil Med*. 2022;54:jrm00276.
44. Aoyama T, Kanazawa A, Kohno Y, Watanabe S, Tomita K, Kimura T et al. Feasibility case study for treating a patient with sensory ataxia following a stroke with kinesthetic illusion induced by visual stimulation. *Prog Rehabil Med*. 2020;5:20200025.
45. Kaneko F, Blanchard C, Lebar N, Nazarian B, Kavounoudias A, Romaiguère P. Brain regions associated to a kinesthetic illusion evoked by watching a video of one's own moving hand. *PLoS ONE*. 2015;10(8): e0131970.
46. Hanakawa T. Organizing motor imageries. *Neurosci Res*. 2016;104:56–63.
47. Hanakawa T, Immisch I, Toma K, Dimyan MA, Van Gelderen P, Hallett M. Functional properties of brain areas associated with motor execution and imagery. *J Neurophysiol*. 2003;89(2):989–1002.
48. Hanakawa T, Dimyan MA, Hallett M. Motor planning, imagery, and execution in the distributed motor network: a time-course study with functional MRI. *Cereb Cortex*. 2008;18(12):2775–88.
49. Li C, Jia T, Xu Q, Ji L, Pan Y. Brain-computer interface channel-selection strategy based on analysis of event-related desynchronization topography in stroke patients. *J Healthc Eng*. 2019;2019:3817124.
50. Levin MF, Weiss PL, Keshner EA. Emergence of virtual reality as a tool for upper limb rehabilitation: Incorporation of motor control and motor learning principles. *Phys Ther*. 2015;95(3):415–25.
51. Hayashi M, Mizuguchi N, Tsuchimoto S, Ushiba J. Neurofeedback of scalp bi-hemispheric EEG sensorimotor rhythm guides hemispheric activation of sensorimotor cortex in the targeted hemisphere. *Neuroimage*. 2020;223: 117298.
52. Butler AJ, Page SJ. Mental practice with motor imagery: evidence for motor recovery and cortical reorganization after stroke. *Arch Phys Med Rehabil*. 2006;87(12 Suppl 2):S2-11.
53. Liu H, Song LP, Zhang T. Mental practice combined with physical practice to enhance hand recovery in stroke patients. *Behav Neurol*. 2014;2014: 876416.
54. Kavounoudias A, Roll JP, Anton JL, Nazarian B, Roth M, Roll R. Proprio-tactile integration for kinesthetic perception: an fMRI study. *Neuropsychologia*. 2008;46(2):567–75.
55. Naito E, Roland PE, Grefkes C, Choi HJ, Eickhoff S, Geyer S, et al. Dominance of the right hemisphere and role of area 2 in human kinesthesia. *J Neurophys*. 2005;93(2):1020–34.
56. Radovanovic S, Korotkov A, Ljubisavljevic M, Lyskov E, Thunberg J, Kataeva G, et al. Comparison of brain activity during different types of proprioceptive inputs: a positron emission tomography study. *Exp Brain Res*. 2002;143(3):276–85.
57. Duclos C, Roll R, Kavounoudias A, Roll JP. Cerebral correlates of the “Kohnstamm phenomenon”: an fMRI study. *Neuroimage*. 2007;34(2):774–83.
58. Goble DJ, Coxon JP, Van Impe A, Geurts M, Doumas M, Wenderoth N, et al. Brain activity during ankle proprioceptive stimulation predicts balance performance in young and older adults. *J Neurosci*. 2011;31(45):16344–52.
59. Ramos-Murguialday A, Broetz D, Rea M, Lärer L, Yilmaz O, Brasil FL, et al. Brain-machine interface in chronic stroke rehabilitation: a controlled study. *Ann Neurol*. 2013;74(1):100–8.
60. Sergi F, Krebs HI, Groissier B, Rykman A, Guglielmelli E, Volpe BT, et al. Predicting efficacy of robot-aided rehabilitation in chronic stroke patients using an MRI-compatible robotic device. *Annu Int Conf IEEE Eng Med Biol Soc*. 2011;2011:7470–3.
61. James GA, Lu ZL, VanMeter JW, Sathian K, Hu XP, Butler AJ. Changes in resting state effective connectivity in the motor network following rehabilitation of upper extremity poststroke paresis. *Top Stroke Rehabil*. 2009;16(4):270–81.
62. Miyawaki Y, Yoneta M, Okawada M, Kawakami M, Liu M, Kaneko F. Model-based analyses for the causal relationship between post-stroke impairments and functional brain connectivity regarding the effects of kinesthetic illusion therapy combined with conventional exercise. *Front Syst Neurosci*. 2021;15: 804263.
63. Cervera MA, Soekadar SR, Ushiba J, Millán JDR, Liu M, Birbaumer N, et al. Brain-computer interfaces for post-stroke motor rehabilitation: a meta-analysis. *Ann Clin Transl Neurol*. 2018;5(5):651–63.
64. Yoxon E, Welsh TN. Rapid motor cortical plasticity can be induced by motor imagery training. *Neuropsychologia*. 2019;134: 107206.
65. Ruffino C, Gaveau J, Papaxanthis C, Lebon F. An acute session of motor imagery training induces use-dependent plasticity. *Sci Rep*. 2019;9(1):20002.

## Publisher's Note

Springer Nature remains neutral with regard to jurisdictional claims in published maps and institutional affiliations.

**Ready to submit your research? Choose BMC and benefit from:**

- fast, convenient online submission
- thorough peer review by experienced researchers in your field
- rapid publication on acceptance
- support for research data, including large and complex data types
- gold Open Access which fosters wider collaboration and increased citations
- maximum visibility for your research: over 100M website views per year

**At BMC, research is always in progress.**

Learn more [biomedcentral.com/submissions](https://biomedcentral.com/submissions)

